

## Systematic Review and Meta-Analysis Oral Surgery

# Long-term prognosis of tooth autotransplantation: a systematic review and meta-analysis

**L. A. Machado, R. R. do Nascimento,  
D. M. T. P. Ferreira, C. T. Mattos,  
O. V. Vilella**

Departamento de Ortodontia, Faculdade de  
Odontologia, Universidade Federal  
Fluminense, Centro, Niterói, RJ, Brazil

*L.A. Machado, R.R. do Nascimento, D.M.T.P. Ferreira, C.T. Mattos, O.V. Vilella:  
Long-term prognosis of tooth autotransplantation: a systematic review  
and meta-analysis. Int. J. Oral Maxillofac. Surg. 2016; 45: 610–617. © 2015  
International Association of Oral and Maxillofacial Surgeons. Published by Elsevier  
Ltd. All rights reserved.*

**Abstract.** The aim of this study was to systematically review the prognosis of autotransplanted teeth followed up for a period of 6 years or more. A literature search was conducted in five databases and the eligibility criteria were established. The outcomes evaluated were the survival rate, percentage of abnormal mobility, pulpal conditions, and percentage of root resorption. The searches identified 1848 articles, and after evaluation against the eligibility criteria, six were included. Data related to outcome measures were extracted from the studies and a meta-analysis was performed. Survival rates ranged from 75.3% to 91% and the meta-analysis showed an effect size of 81% ( $P < 0.0001$ ). The percentage ankylosis ranged from 4.2% to 18.2% and the effect size was 4.8% ( $P < 0.0001$ ). Root resorption percentages ranged from 3% to 10% and the effect size was equal to 4% ( $P < 0.0001$ ). It was not possible to perform a meta-analysis of data on pulpal conditions and percentage of teeth with abnormal mobility. The results of this study showed the survival rate to be excellent, considering the observation period. The rates of ankylosis and root resorption, despite their low values, influence the prognosis of transplanted teeth.

**Key words:** tooth; autotransplantation; prognosis; meta-analysis.

Accepted for publication 18 November 2015  
Available online 13 December 2015

Children and young adults may often exhibit congenitally missing teeth or early loss of teeth due to trauma or caries. The most common restorative options include bridges, implants, removable appliances,<sup>1</sup> and space closure.<sup>2</sup> Autotransplantation, a treatment option where a tooth is

surgically moved from one site in the mouth to another in the same individual,<sup>3</sup> is often overlooked as an alternative,<sup>1</sup> although it is an effective treatment. Its value lies in the fact that it enables denture reconstruction using the most biocompatible material, which is the patient's own

tooth.<sup>4</sup> However, tooth transplantation is often perceived as an unpredictable alternative by surgeons unfamiliar with the procedure.<sup>5</sup>

In the 1960s, Slagssvold and Bjercke established a protocol for autotransplanting teeth at the University of Oslo in

Norway.<sup>6-8</sup> This included indications for transplantation, the surgical procedure, and follow-up guidelines. The predictability of the method was further supported by a long-term follow-up study, which showed that the transplanted teeth had a survival rate of 90% and generally did not differ from normal teeth two to four decades later.<sup>9</sup>

Tooth transplantation has many benefits. It can be performed at an early age, when the incidence of trauma is high. Transplanted teeth can be moved orthodontically<sup>10</sup> and retain the potential to induce alveolar bone growth during the eruption process<sup>11,12</sup>; furthermore, the formation of a functional periodontal ligament allows eruption of the tooth, promoting bony infill at deficient sites,<sup>13</sup> and the gingival contour is often superior to that achieved with prosthetic alternatives.<sup>7,14</sup>

However, there are some risks associated with this procedure. The oral surgeon must have considerable knowledge, skill, and patience, and a careful surgical procedure is essential in order to achieve a successful outcome. Failures after initial attempts at performing the procedure are almost always related to surgical complications or difficulties in removal of the graft from the donor site.<sup>14</sup>

During donor tooth extraction, a total rupture of the neurovascular bundle and periodontal fibres occurs, and the success of autotransplantation depends on the tissue healing process after the surgery.<sup>4</sup> Pulp healing is usually characterized by restoration of the canal contents, including the vascular and nerve supply. The predictability of this healing response appears to be strongly related to the dimensions of the apical foramen.<sup>15</sup> Favourable healing of the periodontal ligament depends on the number of viable cells preserved on the root surface. Successful healing may be expected if donor teeth are extracted with minimal mechanical damage to the periodontal ligament.<sup>12</sup>

Damaged periodontal ligament areas and damaged parts of the root surface are attacked by a resorption process, which may affect the cementum and dentine. Thereafter, inflammatory resorption or surface resorption occurs, depending on the pulpal status and depth of the resorption cavity. Inflammatory resorption

takes place if the resorption cavity penetrates the intermediate layer of cementum and comes into contact with the dentinal tubules that are in communication with infected necrotic pulp tissue. However, if the resorption cavity is shallow and does not penetrate the intermediate layer of cementum, a tooth with similar pulpal changes will elicit only surface resorption, as the intermediate layer of cementum will tend to arrest the diffusion of toxic elements.<sup>16</sup> Inflammatory root resorption usually progresses until the root canal is exposed.<sup>17</sup> In surface resorption, a new periodontal ligament space is established.<sup>18</sup>

Ankylosis, another type of commonly observed root resorption,<sup>19</sup> is caused by large injuries to the root surface of a donor tooth during surgery. In this situation, cells programmed to form bone begin attacking some areas of the root, resulting in resorption (like the adjacent bone). However, in the apposition stage, bone, and not dentine, fills the previously resorbed area.<sup>12</sup>

Autotransplanted teeth are often evaluated in the first year postoperative. However, in order to assess the success of tooth autotransplantation, tissue healing processes and their evolution over the years should be examined, since this procedure is more frequently used in children and adolescents.

No systematic reviews assessing these outcomes over the long term appear to have been reported in the literature. In the present study, it was attempted to evaluate long-term survival rates, the degree of mobility, and the pulp and root conditions of autotransplanted teeth with different stages of root formation at the time of surgery.

## Materials and methods

This systematic review is reported in accordance with the Preferred Reporting Items for Systematic Reviews and Meta-Analyses (PRISMA) checklist. The protocol was designed to answer the following PICO question (i.e. patient, problem or population, intervention, comparison, and outcomes): What are the survival rate, degree of mobility, and pulp and root conditions (outcomes) of autotransplanted (intervention) teeth (population) at least 6 years postoperatively?

An extensive literature search of five electronic databases was conducted: PubMed, Scopus, Web of Science, Lilacs, and The Cochrane Library. The search strategy was performed following the syntax rules of each database; the search protocol established for Medline (via PubMed) is shown in Table 1.

The following filters were used in the search strategy: date (1990/01/01 to 2014/07/07) and species (humans) filters in PubMed, and only date (1990–2014) filter for the remaining four databases. The reference lists of relevant review studies were reviewed manually after the selection protocol to identify further potentially relevant articles.

The inclusion criteria were as follows: (1) controlled trials or prospective/retrospective studies; (2) studies reporting at least one of the following: survival rate, pulp condition, mobility, presence of ankylosis, and root resorption of autotransplanted teeth with complete or incomplete root formation; and (3) studies in which all patients were followed up for a period equal to or greater than 6 years.

The exclusion criteria were as follows: (1) case reports, case series, opinion articles, and review articles; (2) studies reporting autotransplanted teeth in patients with systemic diseases, syndromes, or cleft lip and palate; (3) animal studies; (4) studies examining cryopreserved teeth or teeth maintained in culture media; (5) studies reporting autotransplantation of teeth with a history of cysts, tumours, or trauma; (6) studies including sterilized teeth; (7) studies using membranes; (8) studies with intra-alveolar transplantation of teeth with root fractures; (9) studies with the presence of oro-antral fistulae; (10) studies examining tooth autotransplantation associated with maxillary sinus lifting; and (11) teeth subjected to intentional replantation for endodontic treatment. No restrictions on language were made.

First, the titles and abstracts of potential articles were analyzed and studies that did not meet the eligibility criteria were excluded. A full-text analysis was carried out in cases where the abstract was unavailable or suggested that the eligibility criteria were fulfilled. Each title and abstract was reviewed independently by two

Table 1. Search protocol for PubMed.

PubMed	((tooth[ti] or teeth[ti]) and (transplantation, autologous[mh] OR autotransplantation[ti] OR autotransplanted[ti] OR transplantation[mh] OR transplantation[ti] OR transplanted[ti])) AND (tooth[mh] OR tooth[ti] OR teeth[ti] OR bicuspid[mh] OR premolar*[ti] OR incisor[mh] OR incisor*[ti] OR molar, third[mh] OR 'third molar'[ti] OR 'third molars'[ti] OR 'wisdom teeth'[ti] OR 'wisdom tooth'[ti] OR cuspid[mh] OR 'canine teeth'[ti] OR 'canine tooth'[ti] OR 'maxillary canine'[ti] OR 'mandibular canine' OR molar[mh] OR molar*[ti])
--------	--

researchers (L.A.M. and R.R.N.), and the information obtained was compared. Inter-examiner disagreements were resolved in a consensus meeting with another author (O.V.V.).

The Methodological Index for Non-Randomized Studies (MINORS)<sup>20</sup> was used to assess the quality of articles that met the eligibility criteria. Data directly related to measures of the outcomes of interest were recorded and extracted independently by two authors (L.A.M. and C.T.M.). Any disagreement between reviewers at this stage was resolved by discussion.

The outcomes evaluated were as follows: (1) percentage of transplanted teeth that were still present at the time of examination of the total number of transplanted teeth (survival rate), (2) percentage of abnormal mobility, (3) pulp conditions, and (4) percentage of root resorption.

A meta-analysis was performed using Comprehensive Meta Analysis software version 3.2 (Biostat, Inc., Englewood, NJ, USA). Events and the total sample were collected from the studies that reported them in order to achieve a combined effect size of proportion for evaluation of the survival rate and root resorption. A fixed-effects model was used for analysis as only a few studies were comparable. Heterogeneity among studies was recorded, and a sensitivity analysis was performed. Finally, forest plots showing the comparisons were created. Publication bias was assessed using a funnel plot.

## Results

The electronic database searches identified 1848 titles and abstracts (Fig. 1). Of these, 297 titles were duplicated and were, therefore, removed. All remaining titles and abstracts ( $n = 1551$ ) were analyzed, and 1490 did not meet the inclusion criteria. The full texts of 61 studies were assessed, and finally six articles that met the inclusion criteria completely were selected. No additional articles were found in the manual search.

One study, with a mean follow-up time of 6.2 years, did not provide the range (minimum and maximum follow-up).<sup>21</sup> Attempts were made to contact the authors for the required data, but there was no response. Therefore, this study was not included in the systematic review. A detailed summary of the final selected studies is presented in Table 2. This systematic review was based on prospective and retrospective studies due to the absence of controlled trials.

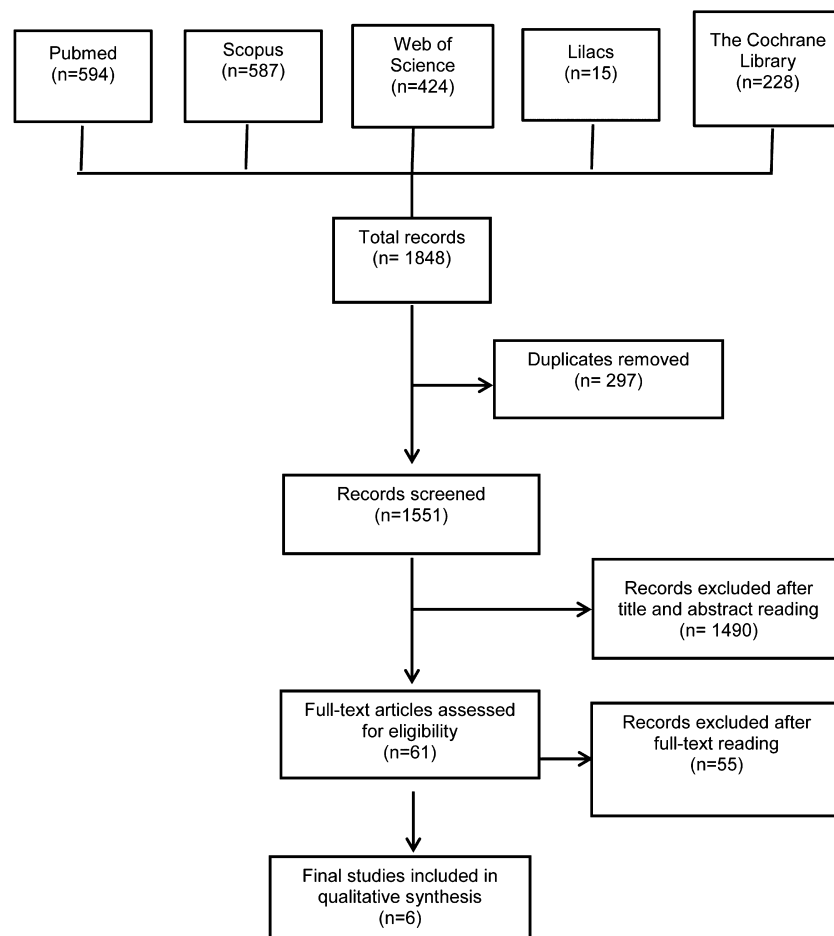


Fig. 1. Flow diagram of selected studies.

The studies of Paulsen et al.<sup>22</sup> and Paulsen and Andreasen<sup>11</sup> involved the same patients; however, some of the outcome measures examined were different and the follow-up period in the latter study was longer. In the study performed by Gonnissen et al., autotransplantations were basically used to correct the position of ectopically impacted canines.<sup>23</sup> All other studies included used autotransplantation to replace missing teeth. Moreover, although Mendoza-Mendoza et al. defined their study as a case series,<sup>24</sup> it was considered a retrospective study by the present authors and was included in this systematic review as such.

The survival rate, mobility rate, pulp condition, and root resorption rates from the individual studies are summarized in Table 3.

The assessment of the quality of articles, in accordance with MINORS,<sup>20</sup> is shown in Table 4. An item was scored as '0' when not reported, '1' when it was inadequately reported, and '2' when it was adequately reported. The articles were

classified according to their methodological quality into low ( $>17$ ), medium ( $\geq 10$  to  $\leq 17$ ), and high risk of bias ( $<10$ ). All studies selected were classified as having a medium risk of bias and were included in this investigation.

The survival rate was mentioned in four studies (Mendoza-Mendoza et al.,<sup>24</sup> Watanabe et al.,<sup>25</sup> Gonnissen et al.,<sup>23</sup> and Czochrowska et al.<sup>9</sup>) and ranged from 75.3% to 91%. The meta-analysis showed a significant effect size of 81% ( $P < 0.0001$ ). Heterogeneity among the studies was low (Fig. 2).

The percentage of abnormal mobility in transplanted teeth was reported in only two studies (Gonnissen et al.<sup>23</sup> and Watanabe et al.<sup>25</sup>). Gonnissen et al. found that 63.3% of the teeth had negative mobility and 3.6% had excessive mobility.<sup>23</sup> Watanabe et al. reported that 18.2% had negative mobility, which was similar to the percentage of ankylosed teeth.<sup>25</sup>

All studies reported the pulp condition of the transplanted teeth. Early endodontic treatment was performed in two studies

Table 2. Characteristics of the studies included.

Author	Study design	Number of patients	Number of teeth	Age range of patients, years	Donor tooth type	Root formation	Follow-up, years
Mendoza-Mendoza et al. (2012) <sup>24</sup>	RS	12	12	9–13	Mx and Md premolars	1/2, 3/4, and complete root length	10–14
Gonnissen et al. (2010) <sup>23</sup>	RS	59	73	11–46	67 Mx impacted canines; 3 Md impacted canines; 2 Md molars	1/2 to 3/4, more than 3/4, complete root formation	6–14 (mean 11)
Watanabe et al. (2010) <sup>25</sup>	RS	32	38	10–43	Mx and Md incisors, premolars, and molars	Complete	6.1–14.5 (mean 9.2)
Czochrowska et al. (2002) <sup>9</sup>	RS	28	33	8–15	2 Mx lateral incisors 10 Mx premolars 16 Md premolars 2 supernumerary teeth	Incomplete	17–41 (mean 26.4)
Paulsen and Andreasen (1998) <sup>11</sup> Paulsen et al. (1995) <sup>22</sup>	PS	NR	118	NR	Mx and Md premolars	3/4 to 4/4 root development with an open apical foramen	6–18 (1998) 6–16 (1995)

Md, mandibular; Mx, maxillary; NR, not reported; PS, prospective study; RS, retrospective study.

Table 3. Survival rate, degree of mobility, pulpal condition, and root resorption rate of individual studies.

Author	Survival rate	Degree of mobility	Pulpal condition	Root resorption rate
Mendoza-Mendoza et al. (2012) <sup>24</sup>	83.3%	NR	Present teeth ( <i>n</i> = 10): 100% presented pulp obliteration	<i>Replacement resorption</i> : NR <i>Surface resorption</i> : present teeth ( <i>n</i> = 10): 10% <i>Inflammatory resorption</i> : overall cause of extraction of 2 teeth (16.7%)
Gonnissen et al. (2010) <sup>23</sup>	75.3%	Present teeth ( <i>n</i> = 55): 63.6% negative mobility 32.7% normal mobility 3.6% excessive mobility (Periotest)	Non-endodontically treated present teeth (60%) ( <i>n</i> = 33): 3% positive result for cold test 12.1% positive result for electric pulp test 75.8% clear pulsatility 57.5% reduction in size or complete obliteration of pulp chamber	Present teeth ( <i>n</i> = 55): 38.2% (34.6% external resorption and 3.6% internal resorption) Overall cause of extraction of 9 teeth (12.3%)
Watanabe et al. (2010) <sup>25</sup>	86.8%	Present teeth ( <i>n</i> = 33): 18.2% negative mobility (Periotest)	The quality of root filling was significantly correlated with the success rate (no abnormal findings)	<i>Replacement resorption</i> : present teeth ( <i>n</i> = 33): 18.2%; overall cause of extraction of 3 teeth (7.8%) <i>Surface resorption</i> : NR <i>Inflammatory resorption</i> : present teeth ( <i>n</i> = 33): 3%; overall cause of extraction of 1 tooth (2.63%)
Czochrowska et al. (2002) <sup>9</sup>	91%	NR	In the teeth where pulp obliteration was analyzed (the group compared to contralateral teeth, <i>n</i> = 11), 100% showed this alteration	<i>Replacement resorption</i> : present teeth ( <i>n</i> = 30): 6.7%; overall cause of extraction of 2 teeth (6%) <i>Surface resorption</i> : NR <i>Inflammatory resorption</i> : NR
Paulsen and Andreasen (1998) <sup>11</sup> Paulsen et al. (1995) <sup>22</sup>	NR	NR	16 teeth (13.5%) showed pulp necrosis and 1 (0.8%) had partial pulp necrosis	<i>Replacement resorption</i> : present teeth ( <i>n</i> = 118): 4.2% <i>Surface resorption</i> : in the teeth submitted to orthodontic rotation (Paulsen et al. 1995) <i>Inflammatory resorption</i> : present teeth ( <i>n</i> = 118): 3.4%

NR, not reported.

Table 4. Score of each article according to the items of MINORS.

Items of MINORS	Mendoza-Mendoza et al. (2012) <sup>24</sup>	Gonnissen et al. (2010) <sup>23</sup>	Watanabe et al. (2010) <sup>25</sup>	Czochrowska et al. (2002) <sup>9</sup>	Paulsen and Andreasen (1998) <sup>11</sup>	Paulsen et al. (1995) <sup>22</sup>
A clearly stated aim	2	2	2	2	2	2
Inclusion of consecutive patients	2	2	2	2	2	2
Prospective collection of data	2	0	0	0	2	2
Endpoints appropriate to the aim of the study	2	2	2	2	2	2
Unbiased assessment of the study endpoint	0	0	0	0	0	0
Follow-up period appropriate to the aim of the study	2	2	2	2	2	2
Loss to follow-up less than 5%	0	0	0	0	0	2
Prospective calculation of the study size	0	0	0	0	0	0
An adequate control group	2	0	2	2	2	0
Contemporary groups	2	0	2	2	2	0
Baseline equivalence of groups	1	0	2	2	2	0
Adequate statistical analyses	0	2	1	1	0	0
Total	15	10	15	15	16	12

MINORS, Methodological Index for Non-Randomized Studies.

(Gonnissen et al.<sup>23</sup> and Watanabe et al.<sup>25</sup>). Gonnissen et al. performed early endodontic treatment in patients older than 20 years with canines that had closed apices,<sup>23</sup> whereas Watanabe et al. performed early endodontic treatment in all teeth and calcium hydroxide was used to temporarily fill the roots.<sup>25</sup> In the studies conducted by Mendoza-Mendoza et al.<sup>24</sup> and Czochrowska et al.,<sup>9</sup> and in the non-endodontically treated teeth included in the study conducted by Gonnissen et al.,<sup>23</sup> 100%, 100%, and 57.5%, respectively, of the teeth analyzed showed signs of pulp obliteration.

Four studies reported the percentage of replacement resorption (ankylosis) in transplanted teeth (Watanabe et al.,<sup>25</sup> Czochrowska et al.,<sup>9</sup> Paulsen and Andreasen,<sup>11</sup> and Paulsen et al.<sup>22</sup>), ranging

from 4.2% to 18.2%. This complication led to extraction in 7.8% of the teeth evaluated by Watanabe et al.<sup>25</sup> and in 6% of the teeth evaluated by Czochrowska et al.<sup>9</sup> The meta-analysis showed high heterogeneity among studies. Upon exclusion of the study conducted by Watanabe et al.<sup>25</sup> from the meta-analysis, as suggested by the sensitivity analysis, the heterogeneity decreased considerably, and a significant effect size of 4.8% was observed ( $P < 0.0001$ ) (Fig. 3).

Surface resorption was observed in only one tooth in the study performed by Mendoza-Mendoza et al.<sup>24</sup> and in all teeth that suffered orthodontic rotation in the study by Paulsen et al.<sup>22</sup> Inflammatory resorption was observed in the teeth evaluated by Watanabe et al.,<sup>25</sup> Paulsen et al.,<sup>22</sup> and Paulsen and Andreasen,<sup>11</sup>

ranging from 3% to 3.4%. This complication was the overall cause of extraction of two teeth (16.7%) in the study by Mendoza-Mendoza et al.<sup>24</sup> and one tooth (2.63%) in the study by Watanabe et al.<sup>25</sup>

In the study conducted by Gonnissen et al., 34.6% of the teeth showed external root resorption.<sup>23</sup> This was the cause of extraction of 12.3% of transplanted teeth. However, the authors did not specify the type of resorption.

When surface resorption, inflammatory resorption, and external root resorption were considered altogether in the meta-analysis, a significant effect size of 19% was observed ( $P < 0.0001$ ). The heterogeneity among studies, nevertheless, was extremely high. Upon exclusion of the study conducted by Gonnissen et al.<sup>23</sup> from the meta-analysis, as suggested by

Heterogeneity: Q-value: 4.35, df (Q): 3, p-value (Q): 0.225; I squared: 31%; Tau squared: 0.107, Tau: 0.326

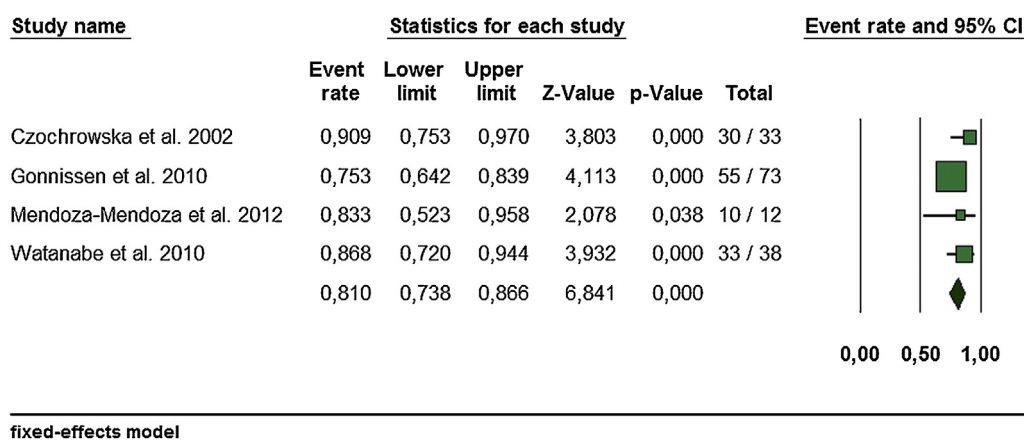


Fig. 2. Forest plot of survival rate (percentage).

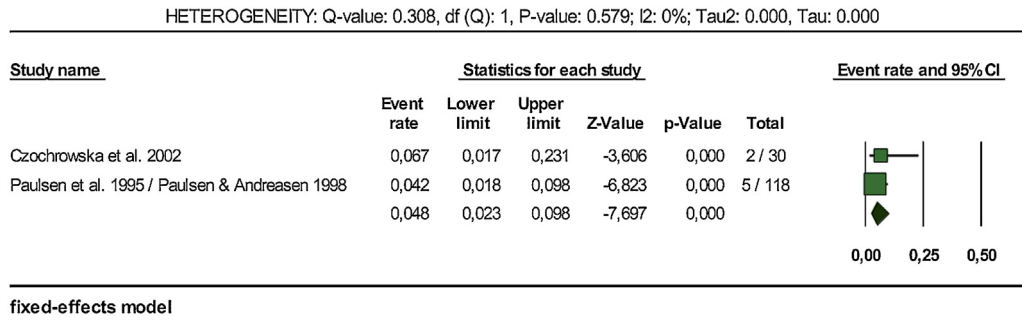


Fig. 3. Forest plot of ankylosis (percentage) after the sensitivity analysis.

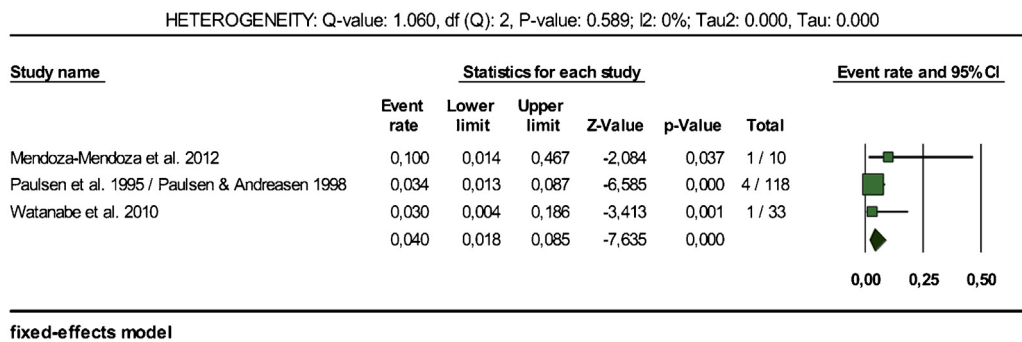


Fig. 4. Forest plot of resorption (percentage) after the sensitivity analysis.

the sensitivity analysis, the heterogeneity decreased considerably and a significant effect size of 4% was observed ( $P < 0.0001$ ) (Fig. 4).

All studies used premolars as donor teeth, except for the study performed by Gonnissen et al. in which 70 impacted canines and two molars were autotransplanted.<sup>23</sup> Two studies used premolars and other types of teeth: Czochrowska et al. used maxillary lateral incisors and supernumerary teeth,<sup>9</sup> whereas Watanabe et al. used molars and incisors.<sup>25</sup>

Overall, the data analyzed were based on three studies in which teeth with incomplete root formation were transplanted (Czochrowska et al.,<sup>9</sup> Paulsen and Andreasen,<sup>11</sup> and Paulsen et al.<sup>22</sup>), one involving teeth with complete root formation (Watanabe et al.<sup>25</sup>), and two involving teeth with complete and incomplete root formation (Mendoza-Mendoza et al.<sup>24</sup> and Gonnissen et al.<sup>23</sup>).

The funnel plot showed a tendency for publication of studies with high survival rates (Fig. 5).

**Discussion**

This systematic review focused on the prognosis of autotransplanted teeth followed up for a period of six or more years. Prospective and retrospective studies identified in accordance with stringent

inclusion criteria were included, and the information available on the survival rate, pulp condition, and the percentage of abnormal mobility and root resorption was summarized.

An effort was made to keep the quality of included studies the best available. However, most studies were retrospective due to the nature of the procedure assessed. The level of bias in retrospective

studies may be very high, which indicates the need for better designed studies addressing this subject.

Another recently published systematic review differs from the present review as the authors analyzed the outcomes of only autotransplanted teeth with complete root formation and a closed apical foramen.<sup>19</sup> Additionally, studies with a follow-up period of at least 1 year (short-term) were

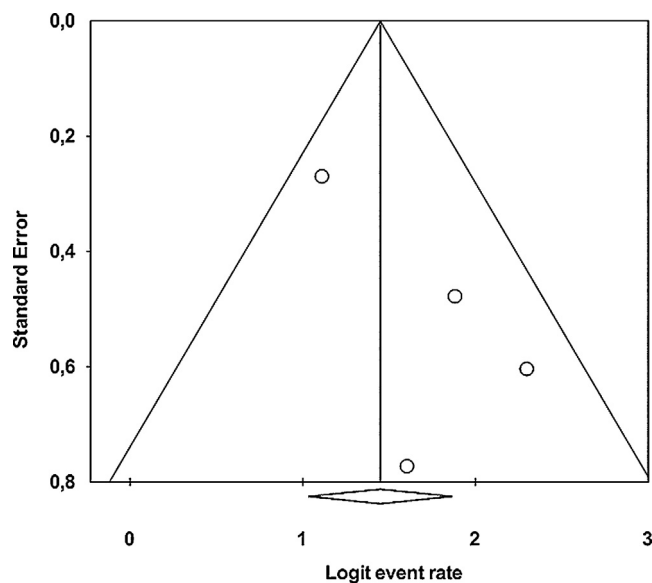


Fig. 5. Funnel plot depicting publication bias.



considered. The first-year outcome rate, annual failure rate, and 5-year estimated survival rate were evaluated.

A factor that needs to be taken into consideration in the long-term evaluation of transplanted teeth is that the tooth removal and insertion in a new site can also be influenced by trauma and changes in occlusion. It is important to note that four studies included in the present review were retrospective (Mendoza-Mendoza et al.,<sup>24</sup> Gonnissen et al.,<sup>23</sup> Watanabe et al.,<sup>25</sup> and Czochrowska et al.<sup>9</sup>). There is no information regarding patients who failed to respond to the recall due to the loss of transplanted teeth, and this could have influenced the findings.

The meta-analysis showed a mean effect of 81% for the survival rate. This is considered to be an excellent prognosis, as the studies included had a minimum follow-up period of 6 years. However, a publication bias was observed, indicating that the publication of studies with lower survival rates was unlikely.

Initially, the meta-analysis showed a mean effect of 8% for ankylosed teeth. However, the heterogeneity among studies was very high and a sensitivity analysis suggested the removal of the study conducted by Watanabe et al.<sup>25</sup> This resulted in a significant effect size of 4.8% (Fig. 3). The study conducted by Watanabe et al. was the only one in which all transplanted teeth had complete root formation, and this condition appeared to be associated with an increase in the percentage of ankylosis in that study (18.2%).<sup>25</sup> The study conducted by Gonnissen et al. was not considered, as it showed greater discrepancy in relation to the others and had a different methodology.<sup>23</sup> Although the authors did not report the percentage of ankylosis directly, they did suggest that observed negative mobility values indicated this condition. The higher percentage of ankylosed teeth observed can be explained by the fact that the study basically included impacted canines, some of which were already ankylosed at the time of transplantation. The periodontal ligament does not exist in some areas in ankylosed teeth and may be thinner and more fragile in impacted teeth.<sup>23</sup> Furthermore, accessibility during surgical extraction of impacted teeth is poor, thereby increasing the chance of root surface damage.

According to Andreasen et al., clinical signs of ankylosis can be observed within a year of tooth autotransplantation.<sup>18</sup> However, it is important to know if this process continues over the years, along with the long-term percentage of loss. Tsukiboshi concluded that ankylosis is

irreversible and will progress until the loss of the tooth.<sup>12</sup> However, in the study by Czochrowska et al., two teeth that exhibited ankylosis shortly after surgery, according to the information available, were still present at 17 and 28 years after transplantation.<sup>9</sup> Tsukiboshi<sup>12</sup> and Czochrowska et al.<sup>9</sup> agree that the gradual progressive resorption in ankylosed teeth can vary with age, with high activity observed in children and significantly lower activity seen in adults, where the affected teeth may survive 10, 20, or more years.

Inflammatory root resorption was observed in four studies (Mendoza-Mendoza et al.,<sup>24</sup> Watanabe et al.,<sup>25</sup> Paulsen et al.,<sup>22</sup> and Paulsen and Andreasen<sup>11</sup>). In the study by Mendoza-Mendoza et al., inflammatory root resorption was seen in teeth with no obliteration in the apical region and was the cause of extraction.<sup>24</sup> However, this condition was not clearly explained when it occurred many years after normal healing. The teeth were extracted 6 and 10 years after transplantation. It is difficult to explain several years of good healing with the development of a cementum/cementoblast layer followed by resorption which suggests its absence. In the study by Watanabe et al., inflammatory resorption was the cause of extraction of one tooth with inadequate root filling.<sup>25</sup> Therefore, in cases where periodontal tissue damage can be observed clinically, it may be interesting to perform endodontic treatment some weeks after transplantation to prevent inflammatory resorption, even with the increased risk of ankylosis.

Surface resorption was observed in only one tooth within the first 6 months in the study by Mendoza-Mendoza et al., and thereafter, it remained stable throughout the observation period.<sup>24</sup> This complication was also found in teeth that suffered orthodontic rotation in the study conducted by Paulsen et al.<sup>22</sup> However, the extent of apical root resorption was similar to that seen in previous investigations of orthodontic treatment of non-traumatized teeth. The positive relationship between orthodontic treatment and surface resorption is to be expected.

In the study by Czochrowska et al., two teeth had crown-to-root ratios greater than one, indicating short roots.<sup>9</sup> However, it is not clear if this condition was caused by root resorption or by arrested root development.

When surface resorption, inflammatory resorption, and external root resorption were combined in the meta-analysis, a mean effect of 19% was observed. However, the sensitivity analysis indicated that

the study by Gonnissen et al.,<sup>23</sup> which accounted for 34.6% of the external root resorption and resulted in the extraction of 12.3% of the transplanted teeth, was the main study responsible for the heterogeneity among studies. The authors did not specify the type of resorption observed. The high rate of root resorption may be explained by the inclusion of ankylosis, also known as replacement resorption (this study basically included impacted canines, some of which were already ankylosed at the time of transplantation). When this study was excluded from the meta-analysis, a mean effect of 4% was observed.

Pulpal healing shows a strong association with the stage of root development and the dimensions of the apical foramen at the time of transplantation.<sup>15</sup> Only one of the finally selected studies showed complete root formation in all transplanted teeth (Watanabe et al.<sup>25</sup>). These were subjected to early endodontic treatment, making the examination of pulp healing impossible. Therefore, it was not possible to compare this aspect.

According to Northway, in cases where a transplant is responding favourably, a positive response to pulp vitality can be detected 2–4 months after transplantation.<sup>26</sup> This is a sign of revascularization, which is generally followed by obliteration of the pulp canal. In the study by Mendoza-Mendoza et al., all transplanted teeth showed pulp obliteration.<sup>24</sup> In the study performed by Czochrowska et al., all transplanted teeth of the group compared to the contralateral control teeth also showed signs of pulp obliteration (this condition was not analyzed in the other group).<sup>9</sup> Both studies used teeth with incomplete root formation (except for one case in the study of Mendoza-Mendoza et al.,<sup>24</sup> where the tooth had complete root formation with an open apex). A lower percentage (57.5%) of teeth with signs of pulp obliteration was observed by Gonnissen et al. in the group of non-endodontically treated teeth.<sup>23</sup> However, this group consisted of transplanted teeth with open apices or closed apices in patients under the age of 20 years. Since revascularization appears to be strongly related to the dimension of the apical foramen,<sup>18</sup> it may not have occurred in the teeth with closed apices.

In some studies, the transplanted teeth received orthodontic loads. The application of force did not affect root development in teeth with incomplete root formation (Mendoza-Mendoza et al.<sup>24</sup>) or influence the long-term prognosis (Watanabe et al.<sup>25</sup>). Gonnissen et al. found

that 62.5% of the transplants that were subjected to orthodontic load were classified as successful, whereas the success rate for all transplanted teeth was 57.5%.<sup>23</sup> Moreover, Paulsen et al. reported slight surface resorption and shortening of the root in teeth that underwent orthodontic rotation.<sup>22</sup> Therefore, the influence of orthodontic movement on transplanted teeth is variable, but is of little clinical relevance.

Based on data collected from prospective and retrospective studies, an excellent survival rate (81%), after a follow-up period of at least 6 years, was observed. Ankylosis (4%) and root resorption (4%) rates, despite their low values, influenced the prognosis of the autotransplanted teeth. However, it must be remembered that the absence of randomized controlled trials (RCTs) may have limited the power of this investigation.

### Funding

Financial support was provided by the authors.

### Competing interests

There are no conflicts of interest for the authors.

### Ethical approval

Not applicable.

### Patient consent

Not required.

*Acknowledgements.* The authors wish to thank Sergio Caetano for his contribution in the translation of articles written in German.

### Appendix A. Supplementary data

Supplementary data associated with this article can be found, in the online version, at <http://dx.doi.org/10.1016/j.ijom.2015.11.010>.

### References

- Schmidt SK, Cleverly DG. Tooth autotransplantation: an overview and case study. *Northwest Dent* 2012;**91**:29–33.
- Northway WM, Konigsberg S. Autogenic tooth transplantation the state of the art.

- Am J Orthod Dentofacial Orthop* 1980;**77**:146–62.
- Howlander M, Begum S, Naulakha D. Autogenous tooth transplantation from ectopic position: a case report and review of literature. *J Bangladesh Coll Phys Surg* 2006;**24**:79–85.
- Chwaja-Pawelec K. Tissue healing after autologous tooth transplantation. *Dent Med Probl* 2010;**47**:359–64.
- Plakwicz P, Wojtowicz A, Czochrowska EM. Survival and success rates of autotransplanted premolars: a prospective study of the protocol for developing teeth. *Am J Orthod Dentofacial Orthop* 2013;**144**:229–37.
- Slagsvold O, Bjercke B. Autotransplantation of premolars with partly formed roots. A radiographic study of root growth. *Am J Orthod* 1974;**66**:355–66.
- Slagsvold O, Bjercke B. Indications for autotransplantation in cases of missing premolars. *Am J Orthod* 1978;**74**:241–57.
- Slagsvold O, Bjercke B. Applicability of autotransplantation in cases of missing upper anterior teeth. *Am J Orthod* 1978;**74**:410–21.
- Czochrowska EM, Stenvik A, Bjercke B, Zachrisson BU. Outcome of tooth transplantation: survival and success rates 17–41 years posttreatment. *Am J Orthod Dentofacial Orthop* 2002;**121**:110–9.
- Andreasen JO, Schwartz O, Kofoed T, Daugaard-Jensen J. Transplantation of premolars as an approach for replacing avulsed teeth. *Pediatr Dent* 2009;**31**:129–32.
- Paulsen HU, Andreasen JO. Eruption of premolars subsequent to autotransplantation. A longitudinal radiographic study. *Eur J Orthod* 1998;**20**:45–55.
- Tsukiboshi M. Autotransplantation of teeth: requirements for predictable success. *Dent Traumatol* 2002;**18**:157–80.
- Day PF, Kindelan SA, Spencer JR, Kindelan JD, Duggal MS. Dental trauma. Part 2. Managing poor prognosis anterior teeth—treatment options for the subsequent space in a growing patient. *J Orthod* 2008;**35**:143–55.
- Czochrowska EM, Stenvik A, Album B, Zachrisson BU. Autotransplantation of premolars to replace maxillary incisors: a comparison with natural incisors. *Am J Orthod Dentofacial Orthop* 2000;**118**:592–600.
- Andreasen JO, Paulsen HU, Yu Z, Bayer T, Schwartz O. A long-term study of 370 autotransplanted premolars. Part II. Tooth survival and pulp healing subsequent to transplantation. *Eur J Orthod* 1990;**12**:14–24.
- Andreasen JO. Relationship between surface and inflammatory resorption and changes in the pulp after replantation of permanent incisors in monkeys. *J Endod* 1981;**7**:294–301.
- Finucane D, Kinirons MJ. External inflammatory and replacement resorption of luxated, and avulsed replanted permanent incisors: a review and case presentation. *Dent Traumatol* 2003;**19**:170–4.
- Andreasen JO, Paulsen HU, Yu Z, Schwartz O. A long-term study of 370 autotransplanted premolars. Part III. Periodontal healing subsequent to transplantation. *Eur J Orthod* 1990;**12**:25–37.
- Chung WC, Tu YK, Lin YH, Lu HK. Outcomes of autotransplanted teeth with complete root formation: a systematic review and meta-analysis. *J Clin Periodontol* 2014;**41**:412–23.
- Slim K, Nini E, Forestier D, Kwiatkowski F, Panis Y, Chipponi J. Methodological index for non-randomized studies (MINORS): development and validation of a new instrument. *ANZ J Surg* 2003;**73**:712–6.
- Schatz JP, Joho JP. Long-term clinical and radiologic evaluation of autotransplanted teeth. *Int J Oral Maxillofac Surg* 1992;**21**:271–5.
- Paulsen H, Andreasen JO, Schwartz O. Pulp and periodontal healing, root development and root resorption subsequent to transplantation and orthodontic rotation: a long-term study of autotransplanted premolars. *Am J Orthod Dentofacial Orthop* 1995;**108**:630–40.
- Gonnissen H, Politis C, Schepers S, Lambrechts I, Vrielinck L, Sun Y, et al. Long-term success and survival rates of autogenously transplanted canines. *Oral Surg Oral Med Oral Pathol Oral Radiol Endod* 2010;**110**:570–8.
- Mendoza-Mendoza A, Solano-Reina E, Iglesias-Linares A, Garcia-Godoy F, Abalos C. Retrospective long-term evaluation of autotransplantation of premolars to the central incisor region. *Int Endod J* 2012;**45**:88–97.
- Watanabe Y, Mohri T, Takeyama M, Yamaki M, Okiji T, Saito C, et al. Long-term observation of autotransplanted teeth with complete root formation in orthodontic patients. *Am J Orthod Dentofacial Orthop* 2010;**138**:720–6.
- Northway WM. Autogenic dental transplants. *Am J Orthod Dentofacial Orthop* 2002;**121**:592–3.

### Address:

Letícia Alves Machado  
Departamento de Ortodontia  
Faculdade de Odontologia  
Universidade Federal Fluminense  
Campus Valonguinho  
Rua Mário Santos Braga  
30  
sala 214  
Centro  
Niterói  
RJ CEP 24040-110  
Brazil  
Tel: +55 21 26221621.  
E-mail: letmachado@bol.com.br